

**JUR** Journal of Unwanted Results  
and Their Correction

**НРЖ** Журнал нежелательных результатов  
и их исправление

Vol. 20, JUR N° 1, May 2026  
English Edition



CORRECTIVE INTERVENTION USING CORTICOBASAL® IMPLANTS,  
AFTER FAILURE OF AN "ALL-ON-4" RECONSTRUCTION,  
REVISION 1

IHDE S., SIPIC O., IHDE A., ZAPPA U.

ISSN 2751-3726 / e-ISSN 2751-3734

Published by IF Publishing, Germany  
continued since 2024 as:

- CMF Implant Directions (CMF)
- Journal of Unwanted Results (JUR)
- Experience-based and evidence-oriented  
Corticobasal® implantology (EECI)



The Foundation of Knowledge

## Editorial Board

### Editor-in-Chief

Prof. Dr. Stefan Ihde  
prof@ihde.com

### Managing Editor

N.N.  
editor@implant-directons.info

### Editorial Board (in Alphabetical Order)

Prof. Dr. Fadia Awadalkreem, Dubai  
Dr. Anita Doshi, India  
Prof. Dr. Antonina Ihde, Belarus  
Prof. Dr. Vitomir S. Konstantinović, Serbia  
Dr. Aleksandar Lazarov, Bulgaria  
Dr. Juri Mitrushchenkov, Russia  
Dr. Mahendra Perumal, India  
Prof. Dr. Olga Šipičić, Serbia  
Prof. Dr. Yan Vares, Ukraine

### Aspirants to the Editorial Board (in Alphabetical Order)

Dr. Salem Barmawi, Lybia  
Dr. Juan Pablo Díaz, Guatemala  
Dr. Marcos Daniel Gonzales, Colombia  
Dr. Georg Huber, Germany  
Dr. Mehul D. Jani, India  
Dr. Valeri Lysenko, Ukraine  
Dr. Kiran Patel, India  
Dr. Faizur Rahman, India  
Dr. Egammai Sethuraman, India  
Dr. Nikolai Spiridonov, Russia

### Evidence Reports and Critical Appraisals

Research & Evidence Department of the  
International Implant Foundation IF®, Munich, Germany

### Annual Subscription

4.600 €

### Copyright

Copyright © 2006 - 2026 by  
International Implant Foundation IF®  
DE- 80802 Munich / Germany  
www.implantfoundation.org

### Contact

publishing@implantfoundation.org

### ЖHP/JUR

ISSN 2751-3726  
e-ISSN 2751-3734

## Disclaimer

### Hazards

Great care has been taken to maintain the accuracy of the information contained in this publication. However, the publisher and/or the distributor and/or the editors and/or the authors cannot be held responsible for errors or any consequences arising from the use of the information contained in this publication. The statements or opinions contained in editorials and articles in this publication are solely those of the authors thereof and not of the publisher, and/or the distributor, and/or the IF®.

The products, procedures and therapies described in this work are hazardous and are therefore only to be applied by certified and trained medical professionals in environment specially designed for such procedures. No suggested test or procedure should be carried out unless, in the user's professional judgment, its risk is justified. Whoever applies products, procedures and therapies shown or described in this publication will do so at their own risk. Because of rapid advances in the medical science, IF® recommends that independent verification of diagnosis, therapies, drugs, dosages and operation methods should be made before any action is taken.

Although all advertising material which may be inserted into the work is expected to conform to ethical (medical) standards, inclusion in this publication does not constitute a guarantee or endorsement by the publisher regarding quality or value of such product or of the claims made of it by its manufacturer.

### Legal restrictions

This work was produced by IF Publishing, Munich, Germany. All rights reserved by IF Publishing. This publication, including all parts thereof, is legally protected by copyright. Any use, exploitation or commercialization outside the narrow limits set forth by copyright legislation and the restrictions on use laid out below, without the publisher's consent, is illegal and liable to prosecution. This applies in particular to photostat reproduction, copying, scanning or duplication of any kind, translation, preparation of microfilms, electronic data processing, and storage such as making this publication available on Intranet or Internet.

Some of the products, names, instruments, treatments, logos, designs, etc. referred to in this publication are also protected by patents and trademarks or by other intellectual property protection laws (eg. «IF», «IIF» and the IF-Logo) are registered trademarks even though specific reference to this fact is not always made in the text.

Therefore, the appearance of a name, instrument, etc. without designation as proprietary is not to be construed as a representation by publisher that it is in the public domain.

Institutions' subscriptions allow to reproduce tables of content or prepare lists of articles including abstracts for internal circulation within the institutions concerned. Permission of the publisher is required for all other derivative works, including compilations and translations. Permission of the publisher is required to store or use electronically any material contained in this journal, including any article or part of an article. For inquiries contact the publisher at the address indicated.



## Corrective Intervention Using Corticobasal® Implants, After Failure of an “All-On-4” Reconstruction, Revision 1

### Authors

Prof. Dr. Stefan Ihde <sup>1,2</sup>

Prof. Dr. Olga Sipic <sup>1</sup>

Prof. Dr. Antonina Ihde <sup>1</sup>

Prof. Dr. Urs Zappa <sup>2\*</sup>

<sup>1</sup> Jaipur Dental College, Department for Prosthetics, Maharaj, Vinayak Global University, Jaipur - 302 021, Rajasthan, India

<sup>2</sup> Private Practitioner at Simpladent® GmbH, 8737 Gommiswald, Switzerland, [www.simpladent.ch](http://www.simpladent.ch)

\* Correspondence: [prof.zappa@bluewin.ch](mailto:prof.zappa@bluewin.ch)

### How to Cite This Article

Ihde S., Sipic O., Ihde A., Zappa U. Corrective Intervention Using Corticobasal® Implants, After Failure of an “All-On-4” Reconstruction, Revision 1. Journal of Unwanted Results and Their Correction (JUR), Vol. 20, No. 1, International Implant Foundation Publishing, 2026

## Revision Index

Revision No.	Changes	Original Article Published	Revision Published
1	<ol style="list-style-type: none"><li>1. Figs. 8 and 9 added</li><li>2. "Message to Take Home" added</li></ol>	May 2025 in Journal of Unwanted Results and Their Correction (JUR), Vol. 19, No. 1, 2025	May 2026 in Journal of Unwanted Results and Their Correction (JUR), Vol. 20, No. 1, 2026

## Abstract

**Background:** The “All-on-4” has become widespread in the last 10 - 15 years. This technology allows a limited form of immediate functional loading. Due to the shortcomings of this technique, we see an amazing amount of failures for this technology on the market and in our clinics. This article shows how a typical failure case can be corrected and developed into a successful case by an expert for Corticobasal® implants.

**Case Presentation:** Four years after receiving an “All-on-4” reconstruction in the lower jaw, a 54-year-old healthy patient requested revision of the lower jaw treatment because the bridge had become mobile and recurrent pain and infections were noticed. The old implants and reconstruction were removed and cortically anchored Strategic Implant® were placed in both the upper and lower jaw. During the next 18 months, radiographic controls were performed and a self-reformation of the formerly lost bone became apparent.

**Conclusion:** Strategic Implant® and the technology of “Osseofixation” are suitable for repairing dental implant cases after conventional osseointegrated implants have failed.

**Keywords:** Strategic Implant®, corrective intervention, failure of conventional dental implants, immediate functional loading, cortical implantology.

## Introduction

The “All-on-4” technology includes placement of four implants in the mandibular interforaminal area or in the area between the maxillary sinuses in the frontal upper jaw. The protocol of this technology includes tilted placement of conventional 2-stage implants, as well as immediate functional splinting of the implants with reduced functional loading. Typically, two bridges are necessary per jaw (!) in order to avoid off-axis forces during the first six months or longer.

The disadvantage of this technology is that the area that has to cope with 90% of the masticatory forces, i.e. the distal aspects of the bridges in both jaws, has no support by implants. This often leads to implant mobilities due to overloading. Hence, overloading of bone and of implant structures (abutments, screws) is one of the main causes of complications.

In this article, we report on the successful repair of a failed “All-on-4” case. The case was rescued and solved with the help of the technology of the Strategic Implant®.

## Case Presentation

The male patient was 54 years old and non-smoker at the onset of our treatment. He did not have a medical history.

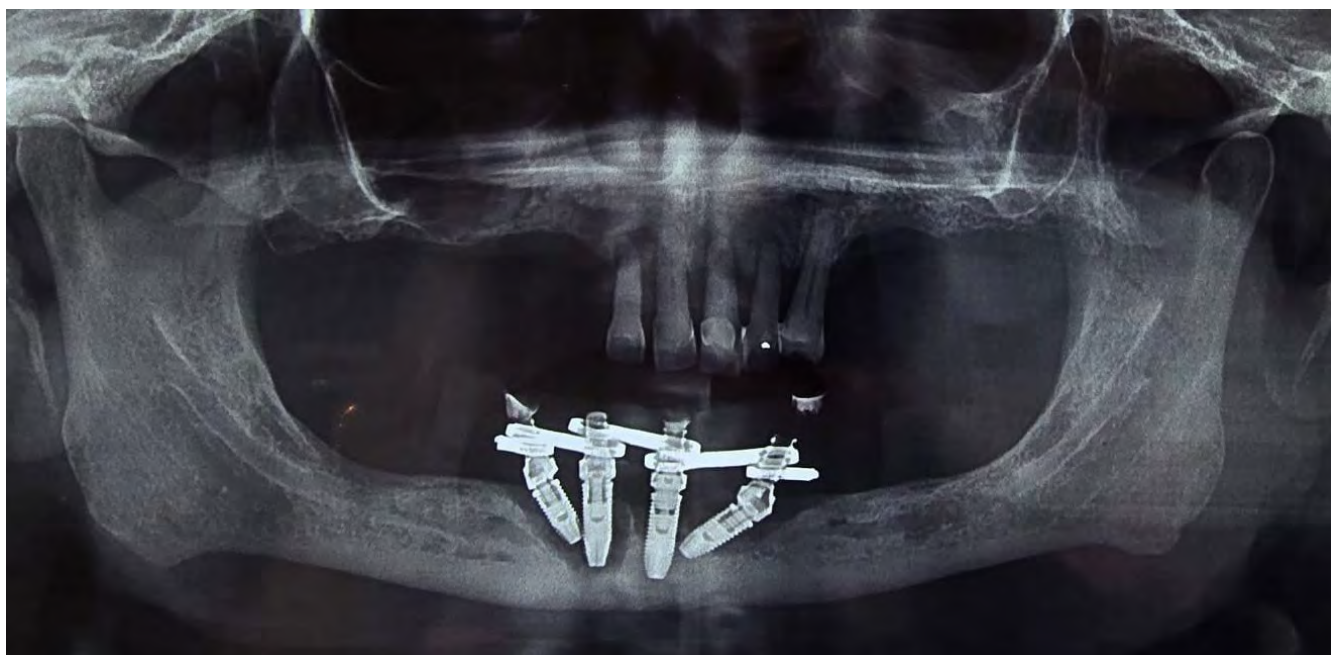**Clinical Findings:** The patient came to the clinic with a mobile, implant-borne bridge in the lower jaw. He complained about recurrent infections with pus flowing out of the mandible. In the upper jaw, he had a few over-elongated front teeth left.

**Diagnostic Assessment:** The patient was sent (as per our routine) to take a new panoramic picture, a cephalometric picture and a PA x-ray of the skull. We did not ask for any documentation from the previous treatment providers, as it was clear that we had to remove all implants and the bridge in the lower jaw as well as all teeth in the upper jaw.

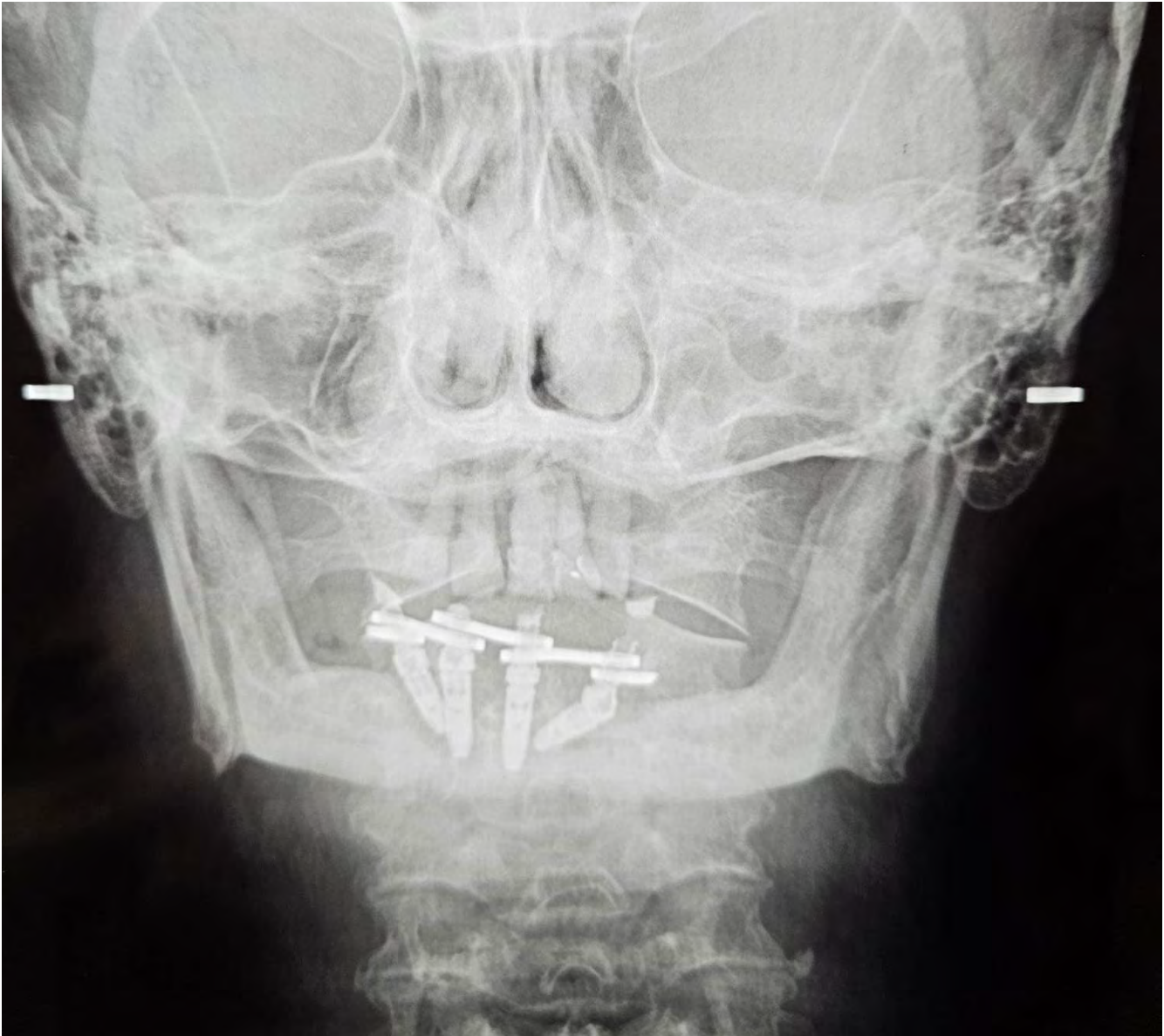
**Therapeutic Intervention:** In local anesthesia and light oral sedation, the bridge and all four implants were removed. Only one of the four implants had still been integrated in its apex area, all other implants were just taken out with the fingers. We inserted seven Strategic Implant® into the lower jaw and all implants achieved high stability.

Right after this, the teeth in the upper jaw were removed, the level of the bone in the upper jaw was adjusted, and treatment given with a total of twelve cortically anchored implants (BCS® and TPG® uno).

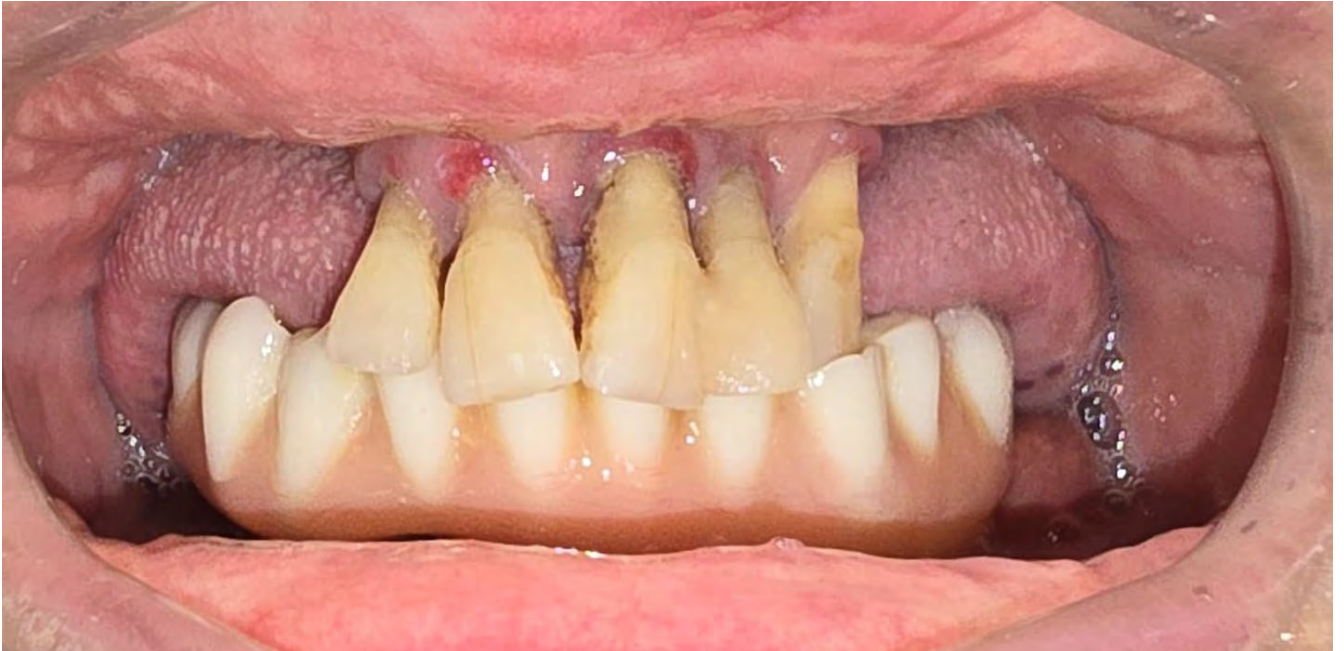**Follow-up and Outcomes:** The healing went well and without complications. The patient's speaking function adjusted quickly to the strongly increased amount of fixed teeth in the oral cavity.



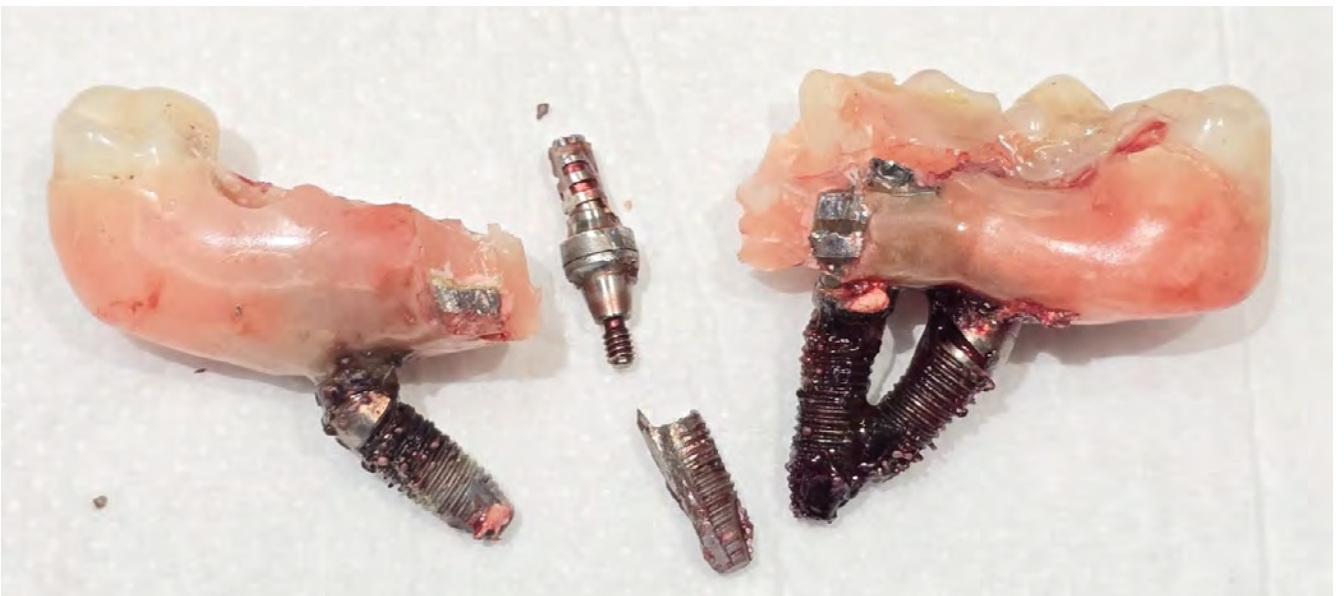**Fig. 1a:** The pre-operative panoramic overview picture shows failing implants, placed according to the technology of "All-on-4", as well as a partly edentulous upper jaw with five teeth left in.



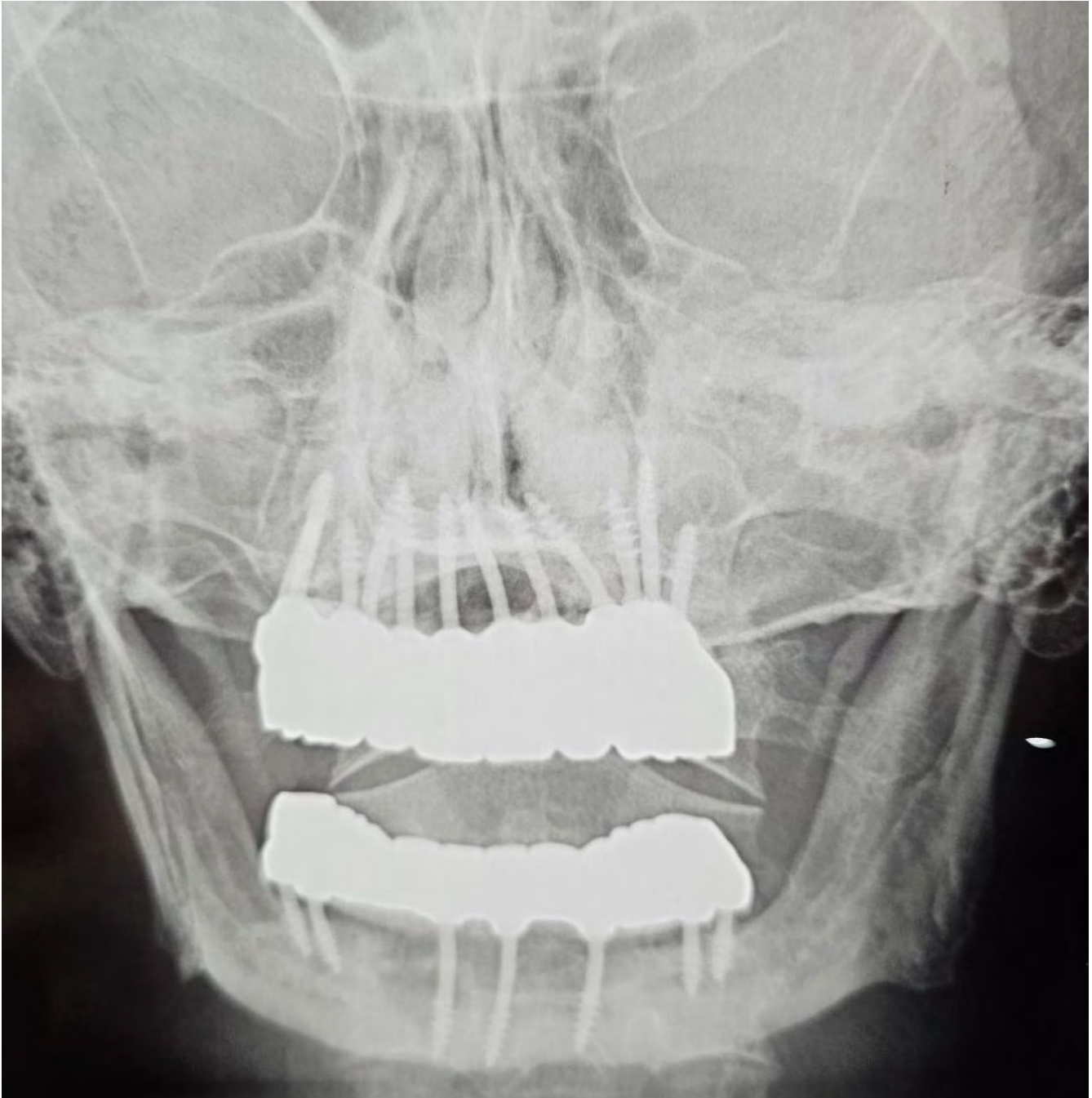
*Fig. 1b: PA radiograph of the skull of our patient, showing massive bone loss and a reduced vertical dimension.*



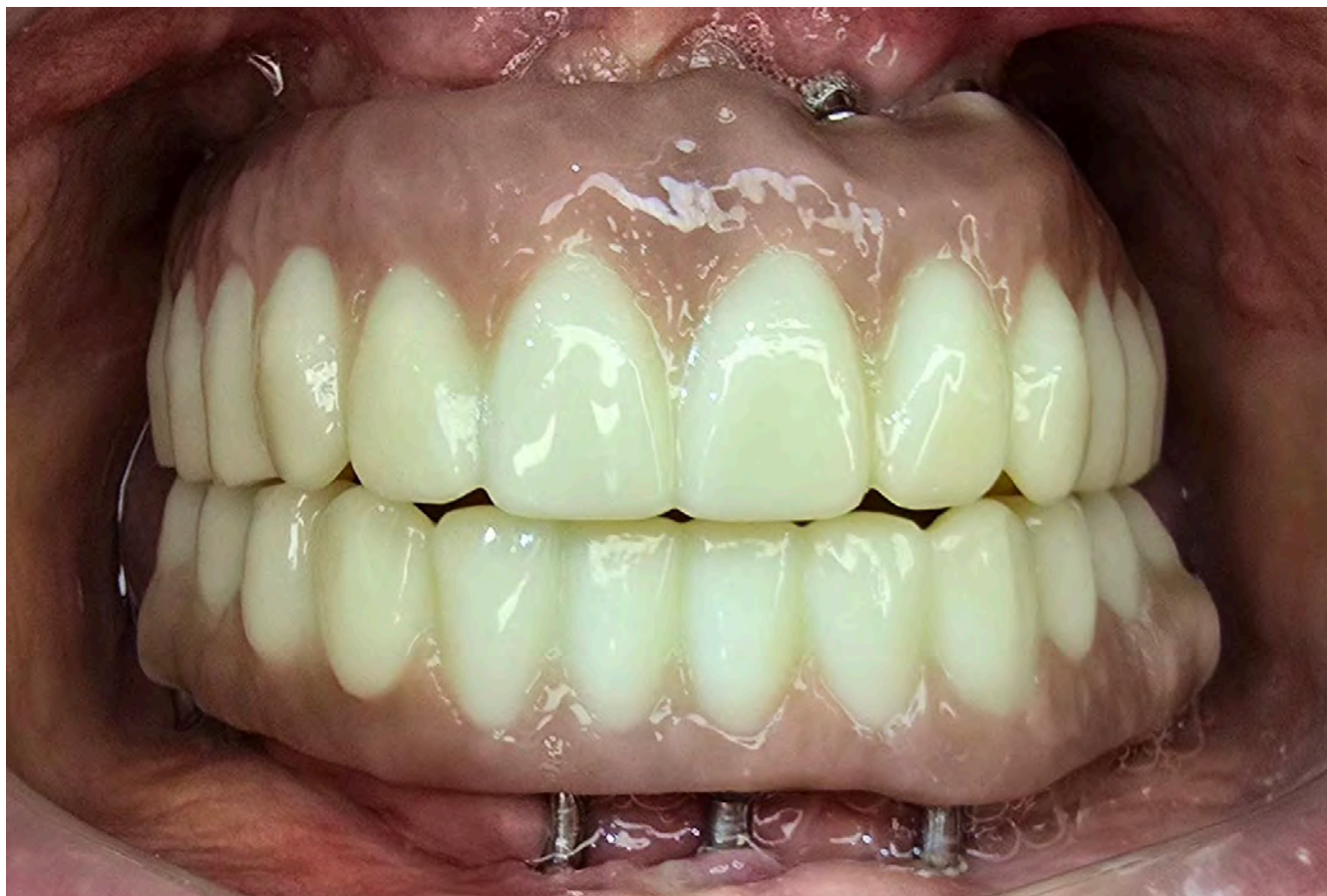**Fig. 2:** Clinical picture before the intervention, showing five upper front teeth with periodontal involvement and signs of chronic infection.



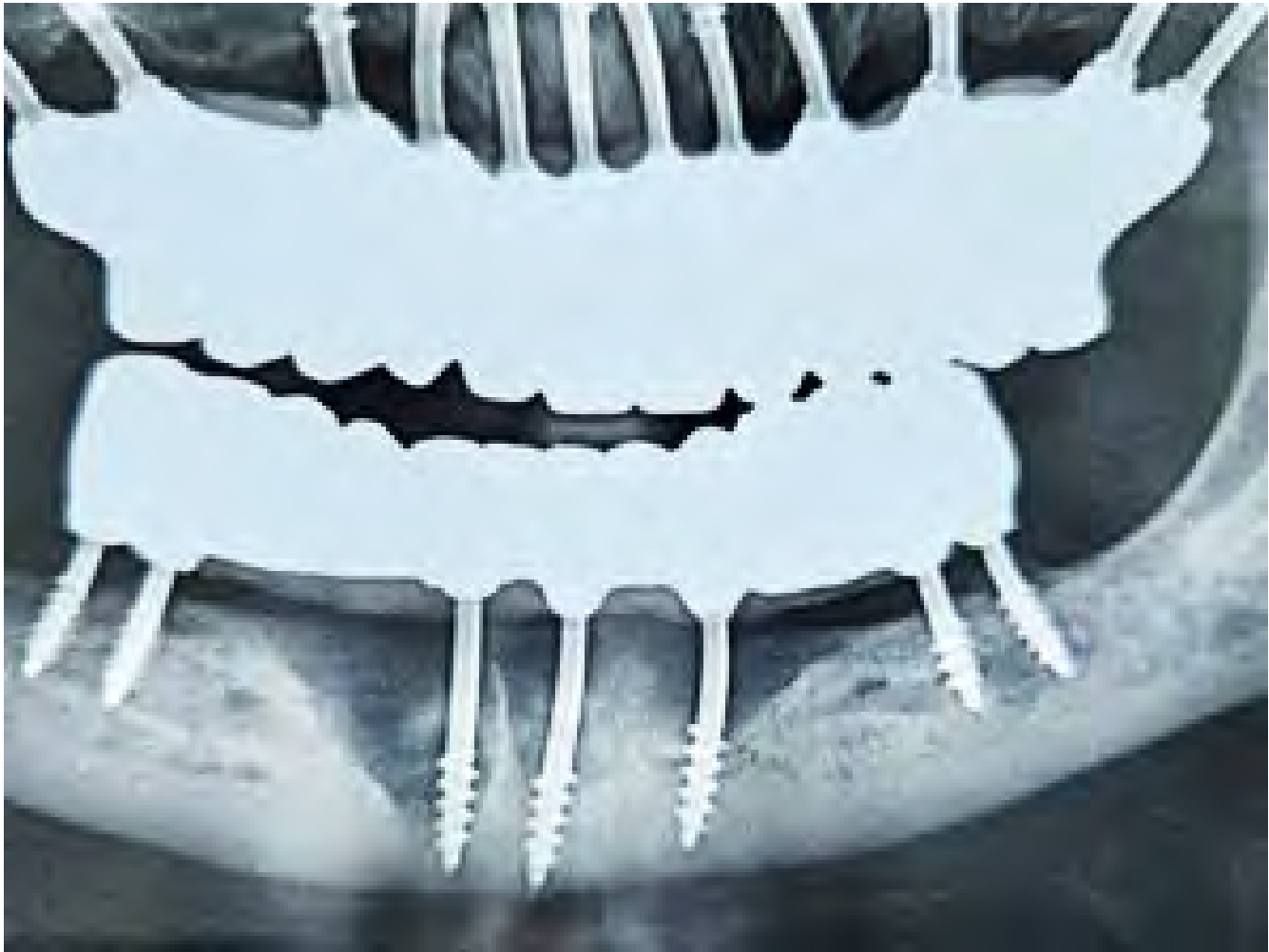**Fig. 3:** All implants had been removed. The acrylic bridge was cut into two parts and removed.



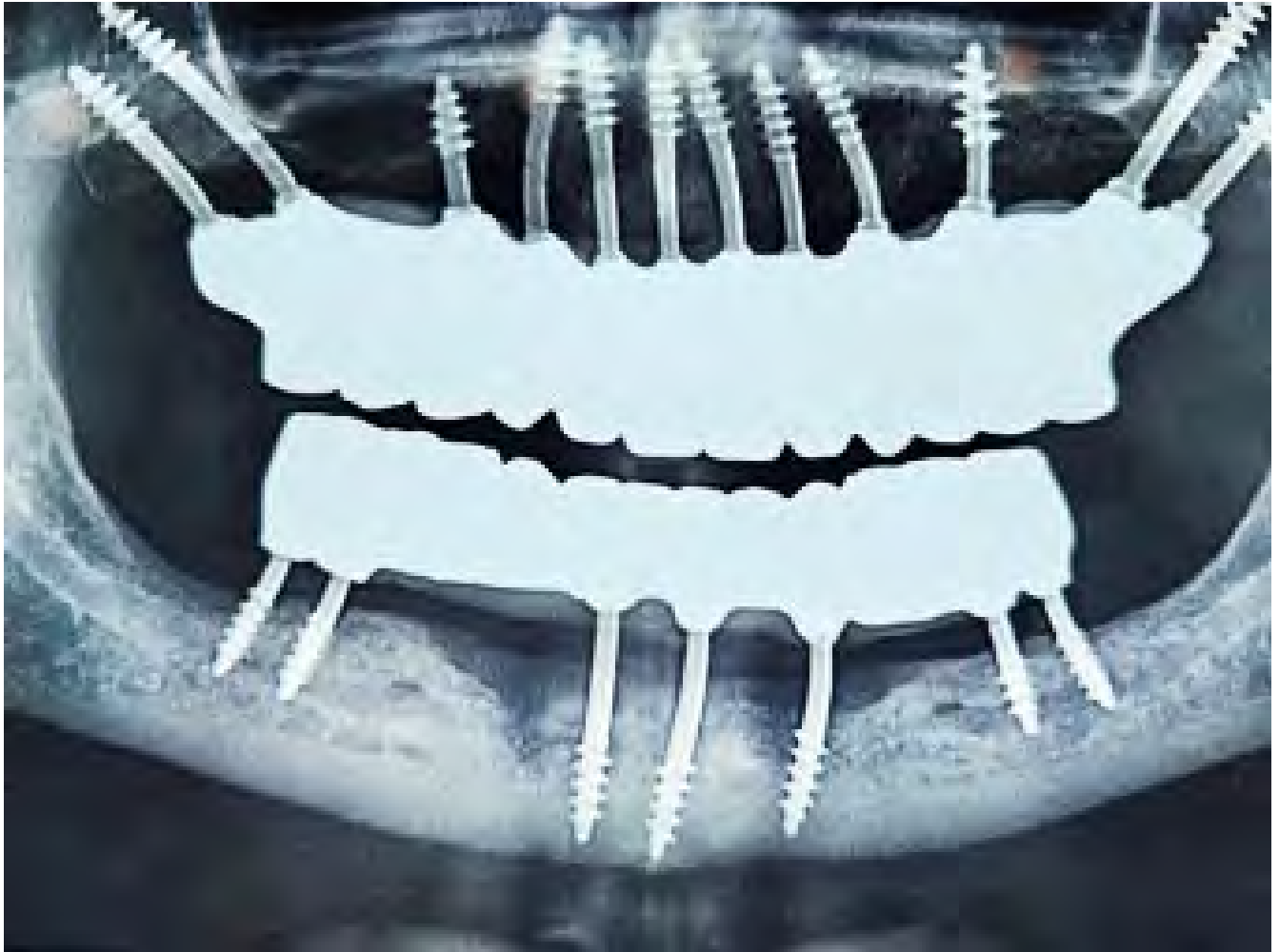*Fig. 4: Post-operative PA of the skull shows implant placement, prosthetic equipment of the two jaws, and the well-adjusted vertical dimension.*



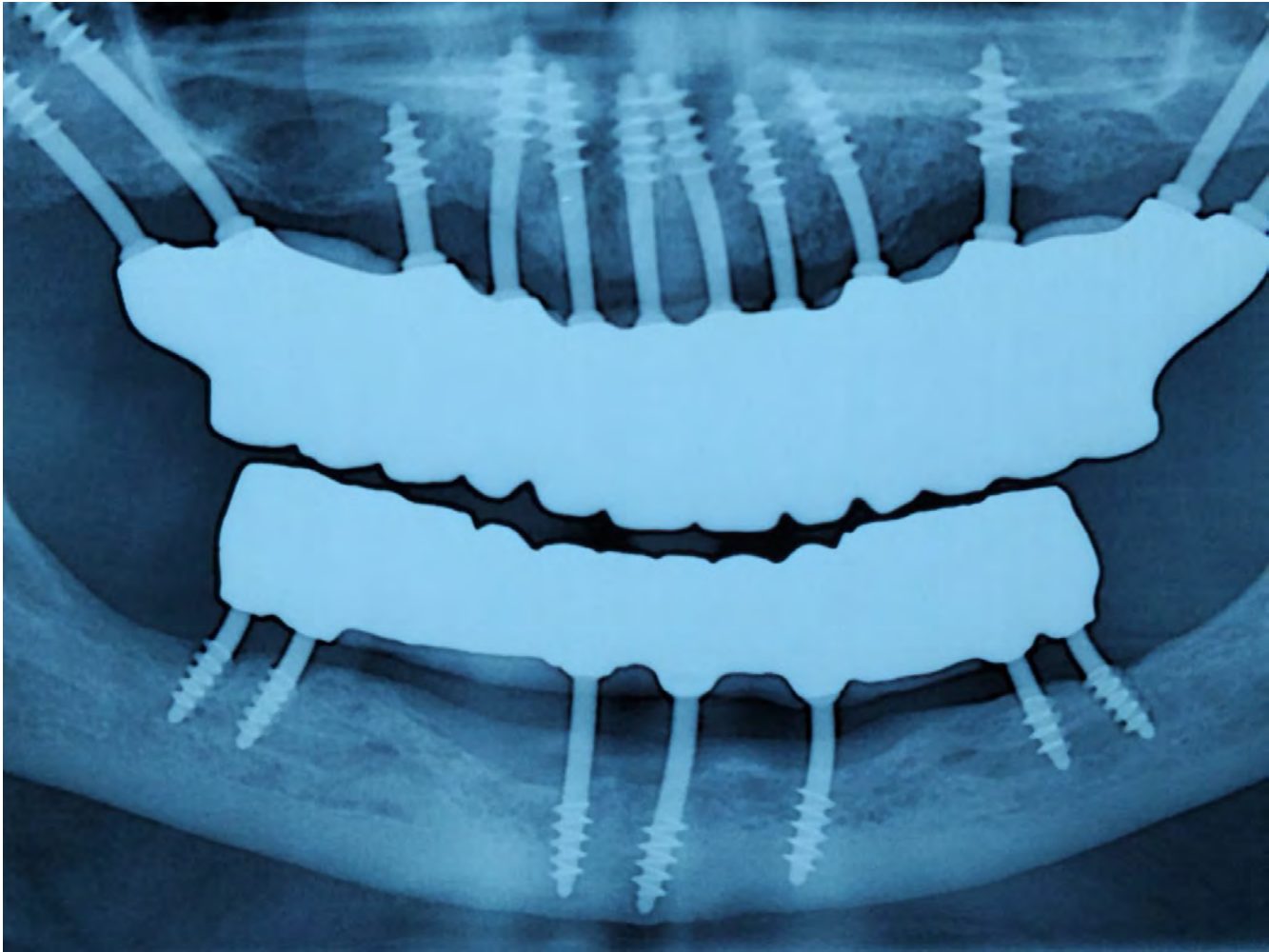
*Fig. 5: Clinical view three months post-operatively. The healing of the gums is uneventful. Contacts are balanced and the patients reports that he can eat everything without any pain.*



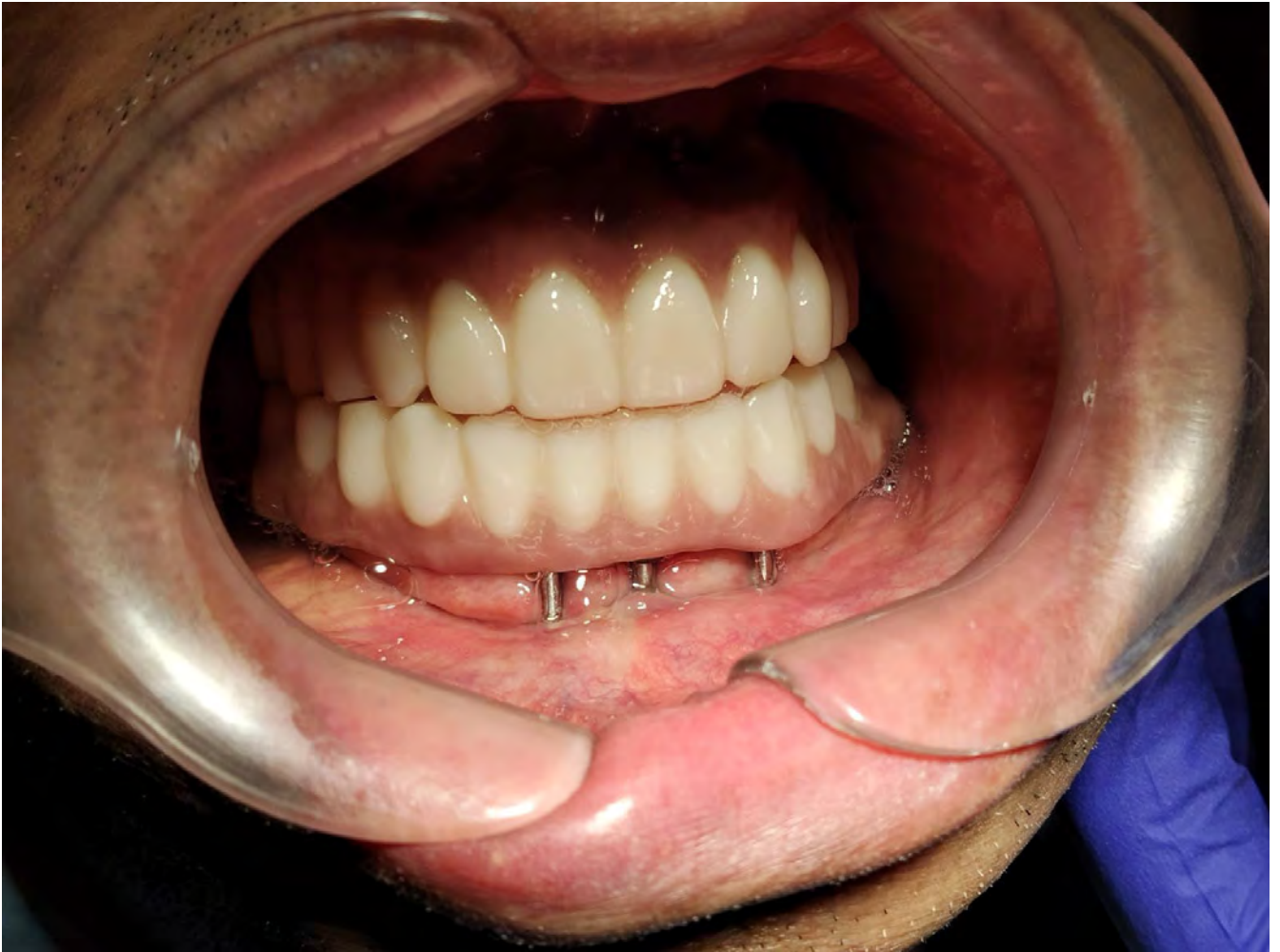*Fig. 6: Post-operative panoramic picture taken on day 3. Severe defects in the mandible are visible. Three implants in the lower front are anchored in the base of the mandible (2nd cortical); all distal implants are placed in IF Method 5a, in lingual cortical engagement.*



*Fig. 7: Twelve months post-operatively, the bony defects in the lower jaw have started to self-fill with new bone. The apposition takes place in all areas of the former defect.*



**Fig. 8:** 25 months after the corrective intervention, vertical bone growth has further increased even to above the level of the threads of the implants. The bone in the anterior mandible shows a very good mineralisation. Most of the damages which were created by the 2-stage implants and periimplantitis have been cured by removing these old types of osseointegrated implants, and placing modern osseofixated implants instead (BECES®, Manufacturer: Simplandent® GmbH, Dorfplatz 11, 8737 Gommiswald / SG, Switzerland) in an immediate functional loading protocol.



**Fig. 9:** Clinical view on the anterior implants and two full zirconium bridges after 25 months. Note that the length of the implants was chosen to allow for a lot of vertical bone growth to happen (which is difficult to foresee) as well as for good and easy cleanability.

## Discussion

**Interpreted Findings:** This case is in line with current literature, which tells that periimplantitis (as well as technical failures of components) are the main reasons for failing conventional implants, especially if the technology “All-on-4” is used.

This case also shows how strong the desire of the jawbone is to reach an adequate level of the crest after the ailing 2-stage implants have been removed. The removal of these implants alone triggers massive new bone formation by itself.

Bone augmentation is not necessary, as the bone is self-healing after the unsuitable and failing implants have been removed.

### **Clinical Significance:**

1. The Strategic Implant® is the device of the first choice when it comes to replacing failing 2-stage implants, because they utilize the available (reduced) amount of bone, they never require bone augmentation and they work in an immediate loading functional protocol.
2. Removal of the old implants and placement of the new implants are

typically done in the same intervention. Right after, the dental lab will start working on the new prosthetic work pieces, which are then cemented onto the abutment heads within 72 hours after the surgical intervention.

3. While the bone level decreases along conventional 2-stage implants, it rises back up to earlier levels of the crest, as soon as the 2-stage implants are removed and replaced by the Strategic Implant®.

## Conclusion

Even in cases of severe bone loss around conventional oral implants, a corrective intervention can be done in one single surgical intervention, using the Strategic Implant® technology.

## Patient Perspective

Our patient came to our clinic from a distance of 2500 km away, just because he knew that we would be able to help him with the superior implant technology (“Implantology 2.0”) of the Strategic Implant®.

The patient came back well in time for the three-month control and then one year later. The bone and soft tissues appeared stable and clean. Some minor adjustments were done on the masticatory surfaces.

## Informed Consent

This article is published with the consent of the patient, who wishes that more dental practitioners would consider to stop treating teeth in order to concentrate on a treatment technology that works without natural teeth and with any remaining amount of jawbone atrophy.

The authors claim that they have no conflict of interest.

## Message to Take Home

2-stage implants are well known to reduce the available bone mass in the jawbones due to periimplantitis. To stop this process of bone loss, all 2-stage implants that are surrounded by periimplantitis (and sometimes all 2-stage implants in general as a prophylactic step to prevent periimplantitis) should be removed. With the BECES® implants, excellent devices are available to reverse the bone loss through natural and undisturbed function without pain.

At the same time, existing infections of the soft tissues and the jawbones are healing, while the BECES® implants are already in full function.

Osseofixated implants (just as osseointegrated implants) do not prevent age-related atrophy of the bone. This means that the bone level will recess over time, especially after extractions. Parts of the implant surfaces will then be exposed to the oral cavity. Due to their thin and polished surfaces, this will not lead to periimplantitis as long as the site is reasonably cleaned and the polished surfaces remains polished. Roughness of endosseous implant surfaces is not required in order to keep dental implants stable and in contact with the bone. Modern osseofixated implants have overcome all flaws of the older method of „osseointegrated implants“. They are the second-generation implants and their technology is superior to the older method. The use of osseofixated implants avoids bone augmentations, unloaded healing time, and periimplantitis [Dobrinin et al; Pałka & Lazarov; Lazarov; Gosai et al.; Ihde, Sipic, Ihde; Ihde & Ihde].

## References

Patzelt, B.M. (2014) The all-on-four treatment concept: a systematic review. *Coin Implant Dent Relaxt Res*, Dec

Malo, P., Araujo, M., Lopes, A., Molina, G. (2011) A longitudinal study of All-on-4 implants in the mandible with up to 10 years follow-up. *Implants* 142,3, 310-320.

Lazarov A. Immediate functional loading: Results for the concept of the Strategic Implant®. *Ann Maxillofac Surg* 2019;9:78-88.

Ihde S, Ihde A, Sipic O. Patient acceptance and outcomes of treatments with Corticobasal® implants. A prospective cohort study. *Natl J Maxillofac Surg* 2025;16:7-13.

Ihde S. (speaker), Sipic O, Ihde A. A Prospective Long-Term Study on the Strategic Implant®, with 17.089 implants observed during on average 9.8 years. This Study Changed the Dental World and the „Gold Standard“ in Oral Implantology. Lecture given at the IF® Workshop in Antalya / Turkey (04/2024), at the World Congress for Immediate Loading Implantology, Munich / Germany (25.10.2025), at the III Congreso Iberoamericano de Implantología Estratégica Corticobasal®, Cartagena / Colombia (21.03.2025), and at the 1<sup>st</sup> North African Conference on the Technology of Corticobasal® Implants, Hammamet / Tunisia (26.04.2025).

Dobrinin O., Lazarov A, Konstantinovic V.K., et al. Immediate-functional loading concept with one-piece implants (BECES/BECES N /KOS/ BOI) in the mandible and maxilla- a multi-center retrospective clinical study. *J. Evolution Med. Dent. Sci.* 2019;8(05):306-315, DOI: 10.14260/jemds/2019/67

Pałka Ł, Lazarov A. Immediately loaded bicortical implants inserted in fresh extraction and healed sites in patients with and without a history of periodontal disease. *Ann Maxillofac Surg* 2019;9:371-8.

Gosai H., Anchilla Sonal, Kiran Patel, Utsav Bhatt, Phillip Chaudhari, Nisha Grag. Versatility of Basal Cortical Screw Implants with Immediate Functional Loading *J. Maxillofac. Oral. Surg.* 2021, <https://doi.org/10.1007/s12663-021-01638-6>

Ihde S, Ihde A. Considerations regarding dental implant surfaces, bone reaction and “Peri-implantitis”. *Ann Maxillofac Surg* 2018;8:365-8



# YOU ARE GOING TO SEE THE LIGHT!

100 % of our course participants understand why conventional dentistry as such is a very doubtful occupation.

We will show you how to stop the breakdown of the masticatory system by doing the „Strategic Reset®“ on modern implants. You will see and understand why natural dentitions break down, and why the results of the Strategic Reset® on modern Implant Corticobasal® implants are lasting.

# ABOUT US

Since 2006, the International Implant Foundation (IF<sup>®</sup>) in Munich, Germany, has been at the forefront of implantology, advancing the field through innovative research and education. Our mission is to provide world-class implantology training for dentists, to support research and continuous exchange of knowledge & experience between professionals, and to inform the general public about the possibilities of modern oral implantology

## 16 Advantages of Osseofixation

Patients will hold you as their treatment provider, because you offer these advantages to them:

- |   |   |  |   |
|---|---|--|---|
| 1   Saves costs by 30-40%               |    | 9   Aesthetic solutions for all patients |    |
| 2   Reduces treatment time by 98%       |  | 10   Uninterrupted intra-bony perfusion  |  |
| 3   Efficient workflow saves chair-time |  | 11   Easy long-term maintenance          |  |
| 4   Immediate functional loading        |  | 12   No peri-implantitis                 |  |
| 5   Low complication rate               |  | 13   No patient selection                |  |
| 6   Simple straight forward treatment   |  | 14   Put more implants                   |  |
| 7   Immediate implant placement         |  | 15   Start treatment immediately         |  |
| 8   Preserves bone elasticity           |  | 16   Cost-effective implants             |  |

# AIOW CURRICULUM



Our All-in-One-Week Curriculum is an intense program designed for dentists to master **tooth-free dentistry**.

This course provides a solid foundation for future learning and patient treatments. With hands-on training and immediate application of skills, you'll be ready to safely implement the latest implantology techniques. Enroll in our advanced dental implants course today.

## Requirements

A valid dental degree is required to enroll in our Corticobasal® implantology training program.

---

## Who Should Attend

- Dentists and oral/maxillofacial surgeons interested in immediate functional loading
  - Prosthetic specialists
- 

## Features

- Instructions from experienced implantologists
  - Learn how to work without bone augmentation
  - Avoid peri-implantitis simply by choosing the right implant
  - Immediate implant placement
  - How to solve cases at all stages of atrophy
- 

## Course Duration

- A full & intense 7-day training program for modern implantology and directly associated subjects.
  - Become a certified implantologist in just one week.
-

# Conventional Implantology



**1** Inspection Diagnostic procedures Treatment plan

**2a** **Surgery 1**  
Tooth removal

**2b** **Surgery 2**  
Bone augmentation/sinus-lifting  
(necessary in up to 80% of the cases)

**2c** **Surgery 3**  
Implant placement  
(adequate bone healing provided)

**2d** **Surgery 4**  
Placement of gingiva former

**2e** Impression taking

**3** Trying of the bridge frame  
(5-10 days after impression taking)

**4** Delivery of bridge (4-24 months after implant placement)

**Total**

Treatment duration: 4 - 24 Months  
Number of appointments: 7 - 12

# Strategic Implant®



Inspection  
Diagnostic procedures  
Treatment plan

**1**

Removal of teeth, Implant placement, Impression & Bite taking

**2**

*\*Step 1 and 2 may be done in the same (first) appointment.*

Trying of a sample bridge and aesthetic & functional corrections (if required) **0 - 1 days** after implant placement

**3**

Delivery of bridge (**1 - 3 days** after implant placement)

**4**

Control of occlusion and mastication

**5**

**Total**

Treatment duration: 2 - 4 Days  
Number of appointments: 4 - 5

# AIOW TEACHERS



## **Prof. Dr. Stefan Ihde**

Surgical & Prosthetic Specialist and  
1<sup>st</sup> Class IF<sup>®</sup> Teacher



## **Prof. Dr. Vitomir Konstantinović**

Professor of Maxillofacial  
Surgery and Implantology,  
Director of the Clinic for Max-  
illofacial Surgery, 1<sup>st</sup> Class IF<sup>®</sup>  
Teacher and Member of the IF<sup>®</sup>  
Board



## **Prof. Dr. Olga Sipić**

Prosthetic Specialist - Implantologist  
and 1<sup>st</sup> Class IF<sup>®</sup> Teacher



## **Prof. Dr. Antonina Ihde**

Prosthetic Specialist, 1<sup>st</sup> Class IF<sup>®</sup> Teacher,  
and Head of Dental Implant Faculty.

7

## Learn from 7 world-renowned professors

in implantology, each bringing extensive experience and expertise to your training. Our faculty includes leading experts in dental implants.



### **DT Sanela Lazinica**

Dentist technician and specialized IF<sup>®</sup> teacher for the work on the Strategic Implant<sup>®</sup>



### **Prof. Dr. Aleksandar Lazarov**

Surgical and prothetical specialist: 1<sup>st</sup> Class IF<sup>®</sup> Teacher, Member of the IF<sup>®</sup> Board



### **Prof. Dr. Yan Vares**

Craniomaxillofacial surgery, Head of Department, Oral Implantology, 1<sup>st</sup> Class IF<sup>®</sup> Teacher



### **Dr. Fodor Romulus Calin**

Surgical and prosthetic specialist, 1<sup>st</sup> Class IF<sup>®</sup> Teacher

WORLD-  
RENOWNED  
PROFESSORS



# SUCCESS STORIES

And Impressions from the course



DR. IONUTS UNGUREAN

*I got to know that this way of implantology is pretty good, I got so excited about it, that I quit my job at a hospital. And I took over a clinic which works only with these implants. Since then I don't do anything else!*



DR. MIGUEL

*It changed my world, because with the Strategic Implant® everything is permitted, anything is possible, you improve oral health of the patient in only 24 hours, and the really important part for me you don't have peri-implantitis. Prof. Ihde forever!*



DR. HABIB RITHA

*I am very lucky to have learned this course. Thank you Dr Ihde for your generosity and your modesty. Thank you all to the team!*

There is no realistic alternative to modern  
Corticobasal® implants and its technology.

---

**Get in Touch:** Register now to our course for tooth-free dentistry  
and long lasting results!

A world map in white silhouette on a dark blue background. A light blue circle with the letters 'SRB' in white is positioned over the Balkan region, indicating the location of the event in Serbia.

SRB

#### LECTURE ROOM:

Golsvordijeva 37, 11000 Belgrade,  
Republic of Serbia

#### PHONE & WEBSITE:

+ 381 69 394 3788 (Whatsapp)  
[all-in-one-week.implantfoundation.org](http://all-in-one-week.implantfoundation.org)  
[implantfoundation.org](http://implantfoundation.org)



SEEING IS  
BELIEVING!